

Original Article

## A CASE REPORT ON THE SURGICAL REMOVAL OF A PERFORATING FOREIGN OBJECT FROM A BEAGLE PUPPY'S INTESTINE

*Harish Chandra Varma, Meena Kumari Joshi and Ajay Krishna Pillai*

Department of Veterinary Surgery and Radiology,  
College of Veterinary and Animal Sciences,  
Mannuthy,

**Abstract:** Gastrointestinal foreign bodies in small companion animals are a common condition requiring prompt diagnosis and surgical intervention. This case report describes the successful surgical removal of a perforating intestinal foreign body in a 35-day-old Beagle pup. The pup presented with symptoms of distended abdomen, blood-tinged diarrhea, and respiratory distress with a history of pain on palpation. Radiographic examination revealed the presence of a radiopaque foreign body in the ileocaecocolic junction, which was tentatively diagnosed as a penetrating intestinal foreign body. An emergency exploratory laparotomy was performed, and a stapler pin was retrieved from the ileocaecocolic junction by enterotomy. The animal received intravenous fluids, antibiotics, H2 antagonists, and vitamin B supplements postoperatively for five days and had an uneventful recovery. The prompt diagnosis and surgical intervention led to the complete recovery of the Beagle pup.

**Keywords:** Penetrating foreign body, gastrointestinal obstruction, small animal practice, surgical intervention, enterotomy.

### Introduction

The ingestion of gastrointestinal foreign bodies is a common condition presented in small animal practice. Animals may present with varying clinical signs depending on the degree and duration of obstruction. Foreign bodies within the gastrointestinal tract may cause tautness, laceration, and perforation, resulting in peritonitis and sepsis. Various treatments have been recommended for gastrointestinal foreign bodies depending on the nature of the foreign body and the risk of gastrointestinal tract obstruction. In this case report, a 35-day-old Beagle pup was presented with symptoms of a penetrating intestinal foreign body. Radiographic examination revealed the presence of a radiopaque foreign body in the ileocaecocolic junction. An emergency exploratory laparotomy was performed, and a stapler pin was retrieved from the ileocaecocolic junction by enterotomy. The animal received postoperative care and had an uneventful recovery. The successful surgical intervention in this case highlights the importance of prompt

## Original Article

diagnosis and surgical retrieval of gastrointestinal foreign bodies to prevent further complications such as peritonitis and dehiscence. The purpose of this case report is to emphasize the importance of timely diagnosis and surgical intervention in gastrointestinal foreign body cases, especially in small companion animals.

### HISTORY AND DIAGNOSIS

A 35 days old Beagle pup weighing 1.4 kg was presented to the University Veterinary Hospital, Mannuthy, Kerala Veterinary and Animal Sciences University with a history of distended abdomen, blood tinged diarrhea and respiratory distress since the previous evening. On physical examination, the pup was dull and depressed with distended abdomen. The mucous membrane was pale and rectal temperature was 37.8<sup>0</sup> C. Abdomen was tensed and on palpation, puppy elicited pain. Radiographic examination of lateral (Fig.1) and ventrodorsal (Fig.2) views of abdomen revealed presence of radiopaque foreign body in the intestinal tract, with size and structure similar to 'Stapler pin'.

The condition was tentatively diagnosed as penetrating intestinal foreign body and emergency laparoenterotomy was decided.

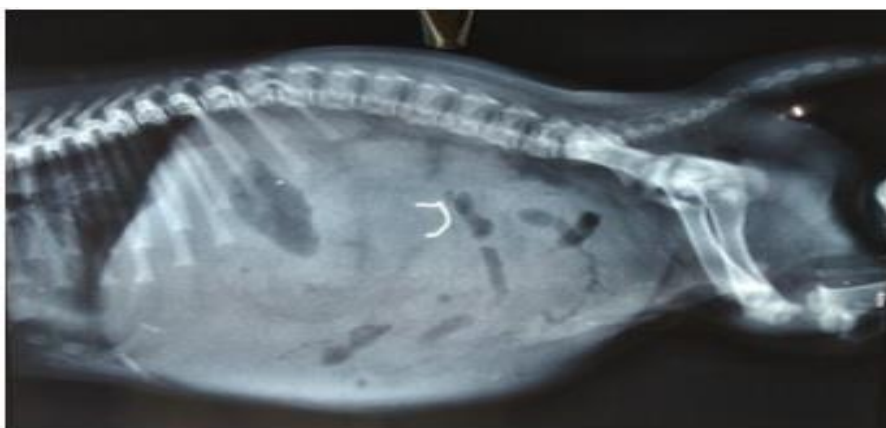


Fig1. Lateral abdominal radiograph showing the radioopaque foreign body

### SURGICAL TECHNIQUE

Preoperatively the animal was stabilized with intravenous Dextrose Saline and antibiotics and prepared the animal for aseptic surgery. Anaesthesia was induced by masking using 3% Isoflurane. Animal was intubated with 4mm cuffed endotracheal tube after induction and anaesthesia was maintained with 1.5-2 % Isoflurane in oxygen. Animal was positioned in dorsal recumbancy and laparotomy was performed through a ventral midline incision. On opening the peritoneal cavity, gastric contents were found spilled out indicating perforation. Lavaged the peritoneal cavity with warm normal saline. A devitalised perforated area was noticed on wall of stomach at the fundus region. The devitalised areas were resected and the defect was closed in connels followed by cushings suture pattern with polyglactin 910 size 3/0. After thorough examination of the GI tract, stapler pin lodged at the ileocaeco-colic junction was located and retrieved through enterotomy (Fig.3). Sutured the enterotomy site with simple continuous pattern using Polyglactin 910 size 3/0. Entire gastrointestinal tract was evaluated for perforation or devitalisation. Repositioned the viscera into the abdominal cavity and sutured peritoneum and muscle layers with simple continuous pattern using polyglactin 910 size 2/0. The skin was apposed in horizontal mattress pattern using monofilament nylon. Post-operatively oral intake was withheld for 72 hours and pup was maintained on intravenous

## Original Article

fluids. Inj. Amoxicillin Sulbactam at a dose rate of 10mg/kg bodyweight, inj. Ranitidine at a dose rate of 0.5mg/kg bodyweight and Vitamin B complex were administered for five days. Sutures were removed on the ninth postoperative day. Pup had an uneventful recovery

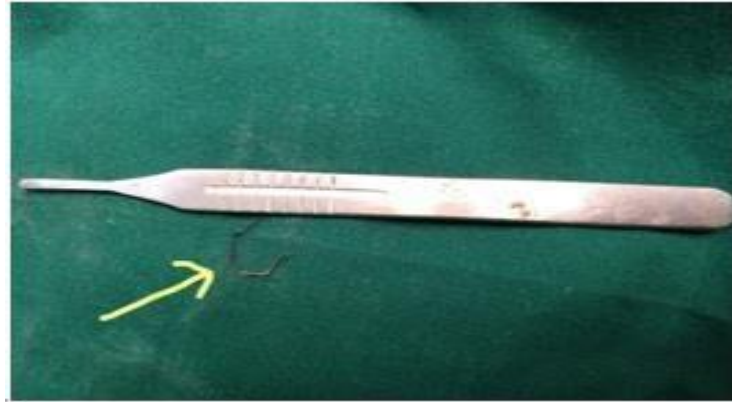

Fig 2. Stapler pin retrieved from ileocaecocolic junction

## DISCUSSION

Gastrointestinal obstruction results in disturbances of fluid balance, acid-base status and electrolyte levels due to hypersecretion and sequestration within the gastrointestinal tract which is exacerbated by vomiting and impaired oral intake of fluid and nutrients (Boag *et al.*, 2005). The presence of a gastrointestinal foreign body, preoperative peritonitis and greater than 15 per cent preoperative weight loss all increase the risk of dehiscence (Allen *et al.*, 1992 and Ralphs *et al.*, 2003).

In the present case, gastrointestinal penetrating foreign body, a stapler pin was found at the ileocaecocolic junction along with a perforation at the body of stomach, which lead to severe peritonitis. Timely diagnosis and surgical retrieval of foreign body saved the animal which had an uneventful recovery.

## REFERENCES

- Allen, D., Smeak, D. and Schertel, E. 1992. Prevalence of small intestinal dehiscence and associated clinical factors: a retrospective study of 121 dogs. *J. Am. Anim. Hosp. Assoc.* **28** (1): 70-76.
- Aronson, L. R., Brockman, D. J. and Brown, D. C. 2000. Gastrointestinal emergencies. *Vet. Clin. N. Am-Small. Anim. Pract.* **30**(3): 555-579.
- Boag, A.K., Coe, R.J., Martinez, T.A. and Hughes, D. (2005) Acid-base and electrolyte abnormalities indogs with gastrointestinal foreign bodies. *J. Vet. Intern. Med.* **19**(6): 816-821 [4] Pratt, C.L., Reineke, E.L and Drobatz, K.J. 2014. Sewing needle foreign body ingestion in dogs and cats: 65 cases. *J. Am. Vet. Med. Assoc.* **245**(3): 302-308 472
- Sudheesh S. Nair, Soumya Ramankutty, Lekshmi S.L and John Martin K.D
- Ralphs, S. C., Jessen, C. R. and Lipowitz, A. J. 2003. Risk factors for leakage following intestinal anastomosis in dogs and cats: 115 cases (1991-2000). *J. Am. Vet. Med. Assoc.* **223**(1): 73-77.