

Original Article

HEPATOPROTECTIVE EFFECTS OF AVOCADO PEAR SEED EXTRACT IN ETHYLENE GLYCOL-TREATED WISTAR RATS

¹Patience R. Ibanga, ²Efe A. Okorodudu and ³Janet K. Ibe

¹Department of Biochemistry, Faculty of Basic Medical Sciences, Bayelsa Medical University, Imgbi Road, Yenagoa, Bayelsa State, Nigeria.

²Department of Biochemistry, Faculty of Basic Medical Sciences, Niger Delta University, Wilberforce Island, Amassoma, Bayelsa State, Nigeria

³Department of Human Physiology, Faculty of Basic Medical Sciences, Niger Delta University, Wilberforce Island, Amassoma, Bayelsa State, Nigeria.

DOI: <https://doi.org/10.5281/zenodo.13829314>

Abstract: The current study was designed to evaluate the possible preventive effects of avocado pear seed ethanolic extracts (ASE) on ethylene glycol (EG) induced hepatotoxicity in Wistar rats. In this study, twenty five male wistar rats were used and divided into five groups of five wistar rats each; a normal control group, a positive control group treated with 0.1ml/kg b.w ethylene glycol only for seven days, two groups treated with different doses of avocado pear seed extract (100mg/kg b.w and 200mg/kg b.w morning and evening respectively) for 21 days and 0.1ml/kg b.w ethylene glycol for 7 days with continuous administration of the treatment dosage and the fifth group treated with 0.2mg/kg b.w folic acid and 0.3mg/kg b.w thiamine (morning and evening) and 0.1ml/kg b.w ethylene glycol for 7 days with continuous administration of the treatment dosage. Ethylene glycol induced liver injury evidenced by histological alterations as well as significant increase of serum indicators of impaired liver function including AST, ALT, ALP, GGT and Bilirubin. Antioxidant activities of superoxide dismutase, glutathione peroxidase and Catalase were significantly declined in the liver as a result of ethylene glycol administrations. Treatment with ethanolic extracts of Avocado pear seed significantly reduced the effect of ethylene glycol induced biochemical and histopathological deleterious alterations; implying the extract reduced toxic effects of ethylene glycol and has potential to stabilize cell membranes and protect the cell /tissues from more damage.

Keywords: Avocado pear, Ethylene glycol, hepatotoxicity, antioxidant.

Introduction

Liver is one major organ credited with huge physiological and biochemical roles that sustains homeostatic status and overall health of living being (Milic *et al*, 2016; Li *et al.*, 2018). Ethylene glycol with a high boiling point of 197°C, that makes it an effective coolant for engines and other high-temperature applications; is also toxic and can be fatal

Original Article

if ingested. When ethylene glycol is metabolized in the body, it is converted into toxic compounds that can cause damage to the body organs and liver in particular (Saidu *et al*, 2007; Egbuonu *et al*, 2009).

Fruits and vegetables have been reported to have protective health benefits (Martin *et al*, 2012). Avocado fruit is from avocado tree (*Persea americana*) belonging to the family Lauraceae as one of the few commercially significant members of the genus *Persea*. Avocado pear is widely cultivated for its edible fruit (Dreher and Davenport, 2013). Although industries that process this ‘foreign pear’ don’t utilize its seed, which has been demonstrated to have numerous bioactive contents (Lara-Marquez *et al*, 2020; Soledad *et al.*, 2021).

Hence, Professor Sule and his team of researchers that have been investigating herbal remedies as natural, alternative source of cardiac/ hepatic / renal health benefits (Sule *et al.*, 2017; Erigbali *et al.*, 2024) considered the avocado fruit; with the aim of investigating whether extract of avocado pear seeds will show health benefits in ethylene glycol-compromised wistar rats and specific objectives was to study its effect on hepatic histo-morphology and serum bio-functional parameters

METHODS

Acclimatized animals placed randomly in five groups were used. Five Wistar rats in Group 1 (control that in normal) were fed with normal animal feed and distilled water *ad libitum*. Group 2 serves as a positive control group and was given 0.1ml/kg b.w of ethylene glycol for seven days, while wistar rats in the treatment group (groups 3 and 4) were fed 100mg/kg (twice daily) extracts of avocado pear seed and 200mg/kg (twice daily) Avocado pear seed extracts respectively for 21 days and 0.1ml/kg ethylene glycol for 7 days with continuous administration of the treatment dosage. Wistar rats in group 5 were given a reference drug of 0.2mg/kg folic acid and 0.3mg/kg thiamine for 21 days and 0.1ml/kg ethylene glycol for 7 days with continuous administration of the reference drug dosage. The exposure was via oral gavage and twice per day was at morning and night.

All wistar rats were subjected to acceptably referenced laboratory experimental and ethical conditions (Sule *et al.*, 2017; Erigbali *et al.*, 2024). After twenty-eight days experiment period, the wistar rats were sacrificed; Blood samples were collected from the heart by cardiac puncture and liver homogenates prepared for analysis, using normal saline buffer and stored in labeled containers for the various antioxidant analysis (Sule *et al.*, 2017; Erigbali *et al.*, 2024).

Estimation of liver function biomarkers was done according to the instruction on the Randox assay kit manual. And Jendrassik & Grof, 1938 approach used for total serum bilirubin. Also standard method was followed for histological examination of liver tissue and photomicrographs captured.

Analysis of Statistics:

Established process (Analysis of variance – one tailed) of testing significance in the mean differences observed and the turkey post hoc test were performed for collated data; using SPSS version 16 as previously adopted (Sule *et al*, 2017). Expression of results was in mean \pm standard error of mean (SEM) and differences deemed significant at $p < 0.05$ (Sule *et al*, 2017).

Original Article

RESULTS

Results of current study are presented below.

Biochemical Analysis:

For AST activity, group 1 (normal control) wistar rats serum values analyzed, showed a lower value of 85.84 ± 4.96 U/L which was significantly different from 176.36 ± 1.31 obtained from the positive control (group 2), ($P < 0.05$).

Treatment of the wistar rats with 100mg/kg b/w (twice daily) avocado pear seed extracts (group 3) and 200mg/kg b/w (twice daily) avocado pear seed extract (group 4), showed a significantly ($P < 0.05$) reduced serum level of 134.96 ± 5.96 U/L and 118.58 ± 3.10 U/L in that order relative to (group 2) of 176.36 ± 1.31 U/L.

Treatment of the wistar rat with 0.2mg/kg b/w Folic acid (twice daily) and 0.3mg/kg b/w thiamine (twice daily (group 5), also showed a lower value of 115.15 ± 2.10 U/L as relative to (group 2) of 176.36 ± 1.31 U/L.

For ALT activity, group 1 (normal control) wistar rats serum values analyzed, showed a lower value of 46.38 ± 1.68 U/L which was significantly different from 131.53 ± 4.26 U/L obtained from the positive control (group 2), ($P < 0.05$).

Treatment of the wistar rats with 100mg/kg b/w (twice daily) avocado pear seed extract (group 3) and 200mg/kg b/w (twice daily) avocado pear seed extract (group 4), gave significantly ($P < 0.05$) decreased serum ALT levels of 84.05 ± 1.76 U/L and 68.89 ± 1.29 U/L respectively as compared to 131.53 ± 4.26 U/L obtained from the positive control (group 2).

Treatment of the wistar rats with 0.2mg/kg b/w Folic acid (twice daily) and 0.3mg/kg b/w thiamine (twice daily (group 5), also gave significantly ($P < 0.05$) reduced serum ALT levels of 81.43 ± 3.11 U/L than Group 2 of 131.53 ± 4.26 U/L.

For ALP activity, group 1 (normal control) wistar rats serum values analyzed, showed a lower value of 91.85 ± 1.29 U/L which was significantly different from 148.39 ± 1.21 U/L obtained in the Group 2, ($P < 0.05$).

Wistar rats treated with 100mg/kg b/w (twice daily) avocado pear seed extract (group 3) and 200mg/kg b/w (twice daily) avocado pear seed extract (group 4), had significantly ($P < 0.05$) reduced serum ALP levels of 84.05 ± 1.76 U/L and 68.89 ± 1.29 U/L respectively as compared to 148.39 ± 1.21 U/L from the positive control (group 2).

Treatment of the wistar rats with 0.2mg/kg b/w Folic acid (twice daily) and 0.3mg/kg b/w thiamine (twice daily), also gave significantly ($P < 0.05$) reduced serum ALP levels of 126.40 ± 1.46 U/L as compared to 148.39 ± 1.21 U/L obtained from the positive control (group 2).

For GGT activity, group 1 (normal control) wistar rats serum values analyzed showed, a lower value of 11.80 ± 0.60 U/L which was significantly different from 39.39 ± 0.48 U/L obtained in the positive control (group 2).

Treatment of the wistar rats with 100mg/kg b/w (twice daily) avocado pear seed extract (group 3) and 200mg/kg b/w (twice daily) avocado pear seed extract (group 4), showed a significantly ($P < 0.05$) reduced serum GGT levels of 20.92 ± 0.87 U/L and 17.49 ± 0.61 U/L respectively as compared to 39.39 ± 0.48 U/L obtained from the positive control (group 2), ($P < 0.005$).

Treatment of the wistar rats with 0.2mg/kg b/w Folic acid (twice daily) and 0.3mg/kg b/w thiamine (twice daily (group 5), also showed a significantly ($P < 0.05$) reduced serum GGT levels of 19.25 ± 0.76 U/L as compared to 39.39 ± 0.48 U/L obtained from the positive control (group 2). For total bilirubin level, serum of the positive control (Group 2) rats were analyzed for total bilirubin level and it showed a significant ($P < 0.05$) increase in values of

Original Article

0.86±0.02g/dL as against the lower value of 0.41±0.01g/dL serum total bilirubin level in the normal control group (Group 1). Analysis of groups 3 with 100mg/kg b/w (twice daily) avocado pear seed extract presented significantly ($P<0.05$) elevated (0.63±0.01g/dL) total bilirubin level and a decrease in total bilirubin value of 0.54±0.02 g/dL level was seen in group 4 where 200mg/kg b/w (twice daily) avocado pear seed extract was used. Treatment with 0.2mg/kg b/w Folic acid (twice daily) and 0.3mg/kg b/w thiamine (twice daily) treated Wistar rats in group 5 showed that it significantly decreased ($P<0.05$) total bilirubin level to 0.54±0.01 g/dL relative to Group 2 values of 0.86±0.02 g/dL.

Antioxidant Analysis:

In Table 2 below, the various Oxidative stress analyses (SOD, CAT, GPx) was carried out on the liver of the wistar rats.

For SOD activity, group 2 (positive control) wistar rats serum values analyzed, showed a lower value of 2.57±0.16 U/mg which is significantly different from 7.12±0.18 U/mg obtained from the Group 1, ($P<0.05$).

Wistar rats treated with 100mg/kg b/w (twice daily) avocado pear seed extract (group 3) and 200mg/kg b/w (twice daily) avocado pear seed extract (group 4), presented with significantly ($P<0.05$) increased SOD (5.35±0.19 U/mg and 5.94±0.31U/mg) respectively as compared to 2.57±0.16U/mg from the positive control (group 2).

Treatment of the wistar rats with 0.2mg/kg b/w Folic acid (twice daily) and 0.3mg/kg b/w thiamine (twice daily) (group 5), also showed an increased SOD levels of 6.18±0.15 as compared to 2.57±0.16U/mg from the positive control (group 2).

For CAT activity, group 1 (normal control) wistar rats serum values analyzed, showed a lower value of 3.05±0.06 U/mg which was significantly different from 6.85±0.21 U/mg obtained from Group 2, ($P<0.05$).

Treating the wistar rats using 100mg/kg b/w (twice daily) avocado pear seed extracts (group 3) and 200mg/kg b/w (twice daily) avocado pear seed extract (group 4), gave significantly ($P<0.05$) increased CAT (5.08±0.06 U/mg and 5.22±0.24 U/mg) respectively as compared to 3.05±0.06 U/mg obtained from the positive control (group 2).

Treatment of the wistar rat with 0.2mg/kg b/w Folic acid (twice daily) and 0.3mg/kg b/w thiamine (twice daily) (group 5), also showed increased CAT levels of 4.96±0.11 U/mg as compared to 3.05±0.06 U/mg obtained from the positive control (group 2).

For GPx activity, group 2 (positive control) wistar rats serum values analyzed showed a lower value of 3.07±0.08 U/mg which is significantly ($P<0.05$) different from 8.07±0.14U/mg obtained from the normal control (group 1).

Treatment of the wistar rats with 100mg/kg b/w (twice daily) avocado pear seed extract (group 3) and 200mg/kg b/w (twice daily) avocado pear seed extract (group 4), showed a significantly ($P<0.05$) increased GPx levels of 4.23±0.11 U/mg and 5.88±0.12 U/mg respectively as compared to 3.07±0.08 U/mg obtained from the positive control (group 2).

Treatment of the wistar rats with 0.2mg/kg b/w Folic acid (twice daily) and 0.3mg/kg b/w thiamine (twice daily) (group 5), also showed a significantly ($P<0.05$) increased GPx levels of 5.87±0.16 U/mg as compared to 3.07±0.08 U/mg obtained from the positive control (group 2).

For MDA activity, group 2 (positive control) wistar rats serum values analyzed, showed a higher value of 5.06±0.19 U/mg which is significantly different from 2.59±0.14 U/mg obtained from the normal control (group 1).

Original Article

Treatment of the wistar rats with 100mg/kg b/w (twice daily) avocado pear seed extract (group 3) and 200mg/kg b/w (twice daily) avocado pear seed extract (group 4), showed a significantly ($P<0.05$) decreased MDA levels of 3.38 ± 0.14 U/mg and 2.28 ± 0.06 U/mg respectively as relative to Group 2 of 5.06 ± 0.19 U/mg.

Treatment of the wistar rats with 0.2mg/kg b/w Folic acid (twice daily) and 0.3mg/kg b/w thiamine (twice daily) (group 5), also presented reduced MDA (2.54 ± 0.13 U/mg) relative to Group 2 of 5.06 ± 0.19 U/mg.

Table 1: Impact of Avocado Pear Seed Extract on Liver Function Biomarkers

Groups/Parameters	AST (U/L)	ALT (U/L)	ALP (U/L)	GGT(U/L)	Bilirubin (g/dL)
Group 1(Normal control)	85.84 ± 4.96^b	46.38 ± 1.68^b	91.85 ± 1.29^b	11.80 ± 0.60^b	0.41 ± 0.01^b
Group 2 (Positive control)	176.36 ± 1.31^a	131.53 ± 4.26^a	148.39 ± 1.21^a	39.39 ± 0.48^a	0.86 ± 0.02^a
Group 3 (100mg/kg b/w extract (twice daily) + EG)	134.96 ± 5.96^{ab}	84.05 ± 1.76^{ab}	134.55 ± 1.38^{ab}	20.92 ± 0.87^{ab}	0.63 ± 0.01^{ab}
Group 4 (200mg/kg b/w extract (twice daily) + EG)	118.58 ± 3.10^{ab}	68.89 ± 1.29^{ab}	100.73 ± 2.55^{ab}	17.49 ± 0.61^{ab}	0.54 ± 0.02^{ab}
Group 5 (Reference drug + EG)	115.15 ± 2.10^{ab}	81.43 ± 3.11^{ab}	126.40 ± 1.46^{ab}	19.25 ± 0.76^{ab}	0.54 ± 0.01^{ab}

Values are given as Mean \pm SEM for each group where SEM is the Standard Error of Mean.

Superscript with different alphabet indicates significant difference ($p<0.05$) within same column.

Key: AST= Aspartate aminotransferase

ALT= Alanine aminotransferase

ALP= Alkaline Phosphatase

GGT = Gamma Glutamyl Transferase

Table 2: Mean Effect of Ethanol Extract of Avocado Pear Seed on Antioxidant analysis (SOD, CAT and GPx) on the Liver of Wistar Rats

Groups/Parameters	SOD (U/mg)	CAT(U/mg)	GPx(U/mg)	MDA(U/mg)
Group 1(Normal control)	7.12 ± 0.18^b	6.85 ± 0.21^b	8.07 ± 0.14^b	2.59 ± 0.14^b
Group 2 (Positive control)	2.57 ± 0.16^a	3.05 ± 0.06^a	3.07 ± 0.08^a	5.06 ± 0.19^a
Group 3 (100mg/kg b/w extract (twice daily) + EG)	5.35 ± 0.19^{ab}	5.08 ± 0.06^{ab}	4.23 ± 0.11^{ab}	3.38 ± 0.14^{ab}

Original Article

Group 4 (200mg/kg b/w extract (twice daily) + EG)	5.94±0.31 ^{ab}	5.22±0.24 ^{ab}	5.88±0.12 ^{ab}	2.28±0.06 ^b
Group 5 (Reference drug + EG)	6.18±0.15 ^{ab}	4.96±0.11 ^{ab}	5.87±0.16 ^{ab}	2.54±0.13 ^b

Values are given as Mean ± SEM for each group where SEM is the Standard Error of Mean. Superscript with different alphabet indicates significant difference ($p < 0.05$) within same column.

KEY SOD = Superoxide dismutase

CAT = Catalase

GPx= Glutathione Peroxidase

MDA= Malondialdehyde

Photomicrographs of the liver sections of rats exposed:

Photomicrograph of liver sections from rats in the normal control showing a normal structure of the portal triad with visible periportal area of the portal vein (PV), portal artery (PA), bile duct (BD): visible hepatocytes (HC), sinusoids (SS), with a diagnosis of normal liver architecture (Fig. 1) while those from Wistar rats in the positive control ethylene glycol induced-group showed a liver morphology with detachment of the centrilobar area of the central vein from the basement membrane and mild vacuolation of the liver paranchyma (Fig. 2). For rats treated with 100 mg/kg (twice daily) ASE, normal blood flow with no central vein congestion and mild sinusoidal dilation is seen as in control (Fig. 3). For rats treated with 200 mg kg b/w(twice daily) and 0.1ml/kg b.w EG of ASE, mild distortion of the liver architecture is seen compared to positive control. (Fig. 4). However, photomicrograph of the liver section from rats treated with the reference drug shows a mild dilatation of bowman's space.

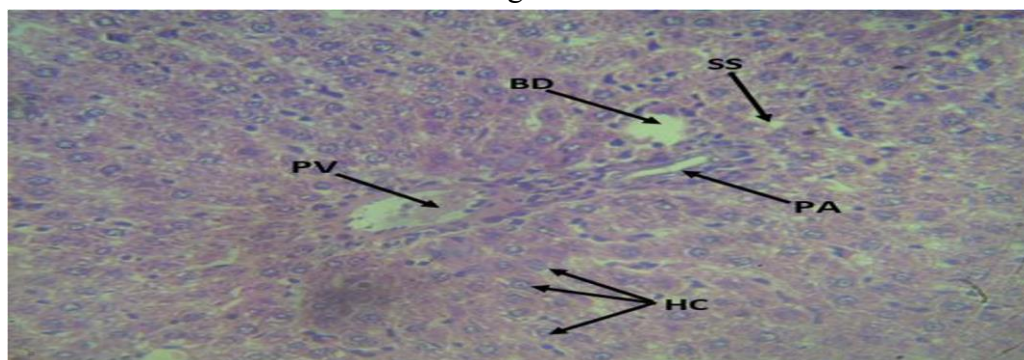


Fig 1: Normal control (Group 1)

Photomicrograph (H&E X400) of the liver showing a normal structure of the portal triad with visible periportal area of the portal vein (PV), portal artery (PA), bile duct (BD): visible hepatocytes (HC), and sinusoids (SS). **Diagnosis:** Normal liver architecture.

Original Article

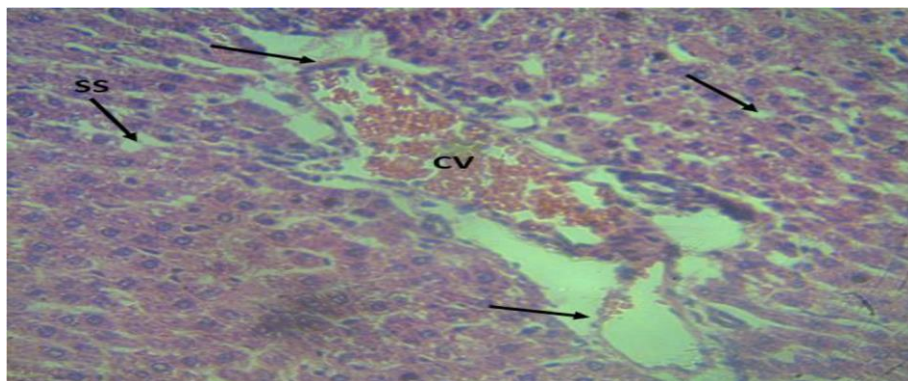


Fig 2: 0.1ml/kg b/w Ethylene glycol Positive control (Group 2)

Photomicrograph (H&E X400) of the liver morphology with detachment of the centrilobar area of the central vein from the basement membrane and mild vacuolation of the liver parenchyma (arrows). **Diagnosis:** Distortion of the liver tissue.

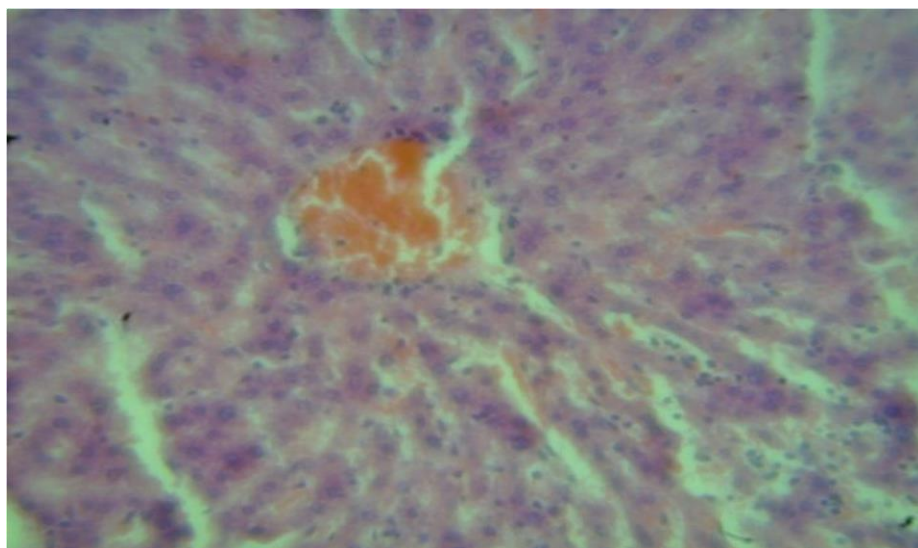


Fig 3: 100mg/kg b/w (twice daily) extract (Group 3)

Photomicrograph (H&E x400) of the liver showing the Central vein with mild and diffused hemosiderin, sinusoidal dilation (arrows) with fine granular eosinophilic cytoplasm

Diagnosis: mild Sinusoidal dilation

Original Article

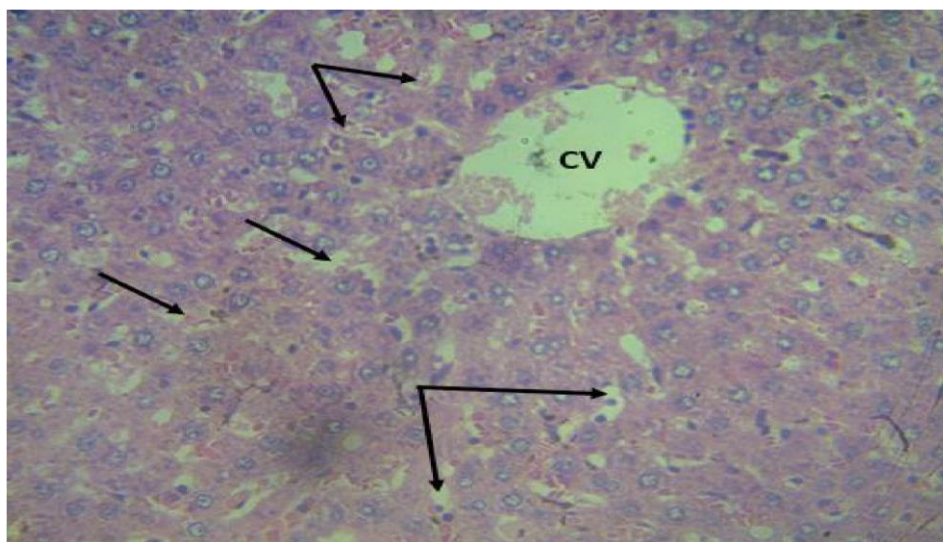


Fig 4: 200 mg/kg (twice daily) extract (Group 4)

Photomicrograph (H&E X400) of the liver morphology with mild and diffused vacuolation.

Diagnosis: mild distortion of the liver architecture.

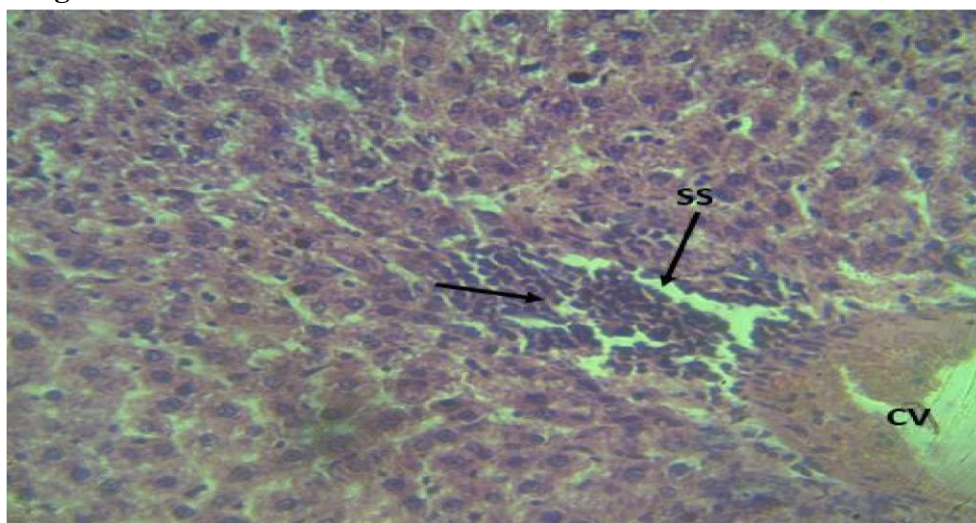


Fig 5: 0.6mg/kg thiamine and 0.4 mg/kg Folic acid (Group 5)

Photomicrograph (H&E X400) of the Kidney with diffused interstitial oedema, mononuclear infiltration of the renal tubules (RT); with mild dilatation of bowman's space.

Diagnostics: Mild dilatation of bowman's space

DISCUSSION

Analaysis of liver biomarkers was implored to appraise avocado pear extract impact on toxin exposed wistar rats; in quest to contribute to the ongoing search for medications which involve natural products (Afolayan & Yakubu, 2009).

In this study, serum values analyzed for AST, ALT, ALP, GGT, showed a lower value for the normal control group which was significantly different from the higher value obtained from the positive control (group 2), ($P < 0.05$).

Original Article

However, treatment of the wistar rats with 100mg/kg b/w (twice daily) avocado pear seed extracts and 200mg/kg b/w (twice daily) avocado pear seed extract, showed significantly reduced serum levels as compared to the value obtained from the positive control (Table1). This lowering of the biomarkers amidst heightened toxicity corroborates studies of Mohamed & Amr, (2013); Gouegni & Abubakar, (2013); Brent *et al.*, (1999).

Antioxidant activities refer to the ability of certain substances to counteract the damaging effects of oxidative stress in the body. Oxidative stress occurs when there is an imbalance between the production of free radicals (reactive oxygen species) and the body's ability to neutralize those using antioxidants. Superoxide dismutase (SOD) is known to catalyze the dismutation of superoxide (O_2^-) to hydrogen peroxide (H_2O_2) and O_2 . SOD is present in most aerobic organisms and is assumed to play a central role in providing defense against oxidative stress (Boguszezwska *et al.*, 2010). In this study, SOD value of the positive control (that was administered ethylene glycol only) was decreased ($p < 0.05$). This shows that ethylene glycol as a toxicant significantly reduces the level of SOD in the serum corroborating the study carried out by Jurczyk *et al.*, (2002) which reported similar toxicity and gradual exhaustion of the antioxidative system. However, treatments of the wistar rats with 100mg/kg b/w (twice daily) avocado pear seed extract and 200mg/kg b/w (twice daily) avocado pear seed extract, and also treatment with the reference drug of with 0.2mg/kg b/w Folic acid (twice daily) and 0.3mg/kg b/w thiamine (twice daily) showed a significantly ($P < 0.05$) increased SOD levels in the liver. This result is in agreement with Wu *et al.* (2007) who report that avocado fruit (leave and seed) act as protective agent by attenuating oxidative stress and have the highest fruit lipophilic antioxidant capacity, which may be one factor in helping to and promoting vascular health which led to increase GPx and SOD activities.

Catalase (CAT) is crucial in defense against oxidative stress; by catalyzing the decomposition of hydrogen peroxide (H_2O_2) into water (H_2O) and molecular oxygen (O_2); particularly in the liver, where it contributes to the protection of cells from the potentially harmful effects of hydrogen peroxide. This enzymatic activity helps prevent the accumulation of hydrogen peroxide and boost antioxidant activities. In this study, the activity of the antioxidant enzyme CAT was depleted in the liver in the positive control group 2 that was administered only ethylene glycol, this was also in tandem with the study carried out by Jurczyk *et al.*, (2002); Wu *et al.*, (2007)

Further analysis for oxidative stress was not different; GPx, or glutathione peroxidase, involved with defense system in the body against stress was depleted in the liver of Group 2 rats, supporting study by Jurczyk *et al.*, (2002). Treatment with the pear at graded dose significantly increased activity of the antioxidant enzyme catalase inside liver in order of dosage; corroborating Wu *et al.* (2007) report that avocado fruit, including its leaves and seed, functions as a protective agent by reducing oxidative stress and exhibiting the highest lipophilic antioxidant capacity among fruits. This attribute contributes to promoting vascular health, leading to elevated activities of GPx (glutathione peroxidase) and SOD (superoxide dismutase).

Lipid peroxidation (MDA) is considered as the main molecular mechanisms involved in the oxidative damage to cell structures and in the toxicity process that lead to cell death. In this study, the oxidative stress indicators / MDA was heightened in group 2 but reversed by treatment with the avocado extract in Group 3 and 4 possibly because of its bioactive constituents (Gupta *et al.*, 2004).

The results of the histopathological studies could possibly represent or demonstrate the nutritional capacity of the wistar rats to synthesize possibly more antioxidant enzymes and metabolites that mitigated free radicals and

Original Article

mediated the toxicant detoxification implying potential to confer cell integrity and possibly protect the cell tissues from more tissue damage.

CONCLUSION

It is conceivable that avocado pear seed extract may have protective potential by conferment of integrity to cell membranes.

ACKNOWLEDGEMENT

The authors wish to acknowledge that this research was funded by Tetfund (Tertiary Education Trust Fund), Nigeria.

REFERENCES

- Boguszewska, D., Grudkowska, M. and Zagdańska, B. (2010). Drought-responsive antioxidant enzymes in potato (*Solanum tuberosum* L.). *Potato Research*. 53, 373–382. doi: 10.1007/s11540-010-9178-6
- Brent, J., McMartin, K., Phillips, S., Aaron, C. and Kulig, K. (1999). Methylpyrazole for Toxic Alcohols Study Group. Fomepizole for the treatment of ethylene glycol poisoning. *New England Journal of Medicine*, 340(11), 832-838.
- Dabas D., Ziegler G.R. and Lambert, J.D (2019). Anti-Inflammatory Properties of a Colored Avocado Seed Extract. *Advances In Food Technology and Nutritional Sciences*. 5(1): 8-12. doi: 10.17140/AFTNSOJ-5-151
- De Haan J. B., Stefanovic, N., Nicolic-Paterson, D. N., Scurr, L. L., Croft, K. D. and Mori, T. A. (2005). Kidney expression of glutathione peroxidase-1 is not protective against streptozotocin-induced diabetic nephropathy. *American Journal of Physiology*, 289, 544-551.
- Dreher, M.L. and A.J. Davenport (2013). Hass avocado composition and potential health effects. *Critical Reviews in Food Science and Nutrition*, 53: 738-750.
- Egbonu, A.C.C., Obidoa, O., Ezeokonkwo, C.A., Ezeanyika L.U.S. and Ejikeme, P.M. (2009). Hepatotoxic effects of low dose oral administration of monosodium glutamate in male albino rats. *African Journal of Biotechnology*. 8: 3031-3035.
- Erigbali P.P., Arhoghro E. M., Sule O.J., & Nordee J.V. (2024) Antioxidant Effect and Nephro Protective Potential of Terminalia Catappa Leaf on Kidneys of Wistar Rats Exposed to Augumentin – induced Damage. *European Journal of Biomedical and Pharmaceutical Sciences*. Volume 11, Issue1: pp. 116 – 121
- Ezuruike, U.F. and Prieto, J.M. (2014). The use of plants in the traditional management of diabetes in Nigeria: Pharmacological and toxicological considerations. *Journal of Ethnopharmacology*, 155: 857-924.
- Ghouri, N., Preiss, D and Sattar, N. (2010). Liver enzymes, nonalcoholic fatty liver disease and incident cardiovascular disease: A narrative review and clinical perspective of prospective data. *Hepatology*, 52: 1156-1161.

Original Article

- Gupta, M., Mazumder, U. K., Kumar, T. S., Gomathi, P. and Kumar, R. S. (2004). Antioxidant and hepatoprotective effects of *Bauhinia racemosa* against paracetamol and carbon tetrachloride induced liver damage in rats. *Iranian Journal of Pharmacological Therapeutics*. **3**: 12- 20.
- Jurczyk, A., Gałeczki, P., Jankowska, B., Meissner, E., Szram, S., Fijałkowski, P., Błaszczyk, J. and Kędziora, J. (2002). Effect of ethylene glycol on antioxidative enzymes and lipid peroxidation activity in erythrocytes. *Archives of Forensic Medicine*, **12**, 1-37.
- Lara-Márquez, M., Báez-Magaña, M., Raymundo-Ramos, C., Spagnuolo, P. A., Macías Rodríguez, L., Salgado-Garciglia, R. and López-Meza, J. E. (2019). Lipid-rich extract from Mexican avocado (*Persea americana* var. *drymifolia*) induces apoptosis and modulates the inflammatory response in Caco-2 human colon cancer cells. *Journal of Functional Foods*, 103658. doi:10.1016/j.jff.2019.103658
- Li, S., Tan, H.Y., Ning, W., Fan, C., Ming, H. and Yibin F. (2018) Review article: The potential and action mechanism of polyphenols in the treatment of liver diseases. *Oxidative Medicine and Cellular Longevity*, **12**(3), 13-19.
- Martin, J.G.P., Porto, E., Correa, C.B., de Alencar, S.M., da Gloria, E.M., Cabraland, I.S.R. and de Aquino, L.M. (2012). Antimicrobial potential and chemical composition of agroindustrial wastes. *Tropical Journal of Natural Product Research*. **5**: 27-36.
- Milic, S., Ivana, M., Lidija, O., Edita, D., Nada, S.C., Davor, S., Miljenko, K. and Smiljana, R. (2016). The role of iron and iron overload in chronic liver disease. *Medical Science Monitor*, **22**, 2144-2215.
- Saidu, Y., Bilbis, L.S., Lawal, M., Isezuo, S.A., Hassan, S.W. and A.Y. Abbas, 2007. Acute and sub-chronic toxicity studies of crude aqueous extract of *Albizzia chevalieri* harms (Leguminosae). *Asian Journal of Biochemistry*, **2**: 224-236.
- Sule O. J., Arhoghro E. M., & Erigbali P. (2017) Nephro-Protective and Hepato-Protective Property of Commelina Diffusa Leaf Extract in Doxorubicin-induced Albino Rats. *World Journal of Pharmacy and Pharmaceutical Sciences*, Volume 6, Issue 10, 51-62
- Tremocoldi, M. A., Rosalen, P. L., Franchin, M., Daiuto, R., Augusto, J. and Massarioli, P. (2018). *Exploration of Avocado by-products as Natural Sources of Bioactive Compounds*, *PLoS One*, **4**(1), 1-12.
- Uchenna, U. E., Shori, A. B. and Baba, A. S. (2017). Inclusion of avocado (*Persea americana*) seeds in the diet to improve carbohydrate and lipid metabolism in rats. *Revista argentina de endocrinología y metabolismo*, **54**(3), 140–148.
- Villarreal-Lara, R., Rodríguez-Sánchez, D. G., Díaz De La Garza, R. I., García-Cruz, M. I., Castillo, A. and Pacheco, A. (2019). Purified avocado seed acetogenins: Antimicrobial spectrum and complete inhibition of *Listeria monocytogenes* in a refrigerated food matrix. *CyTA-Journal of Food*, **17**(1), 228–239

Original Article

Wu, X., Gu, L., Holden, J., Haytowitz, D. B., Gebhardt, S. E., Beecher, G. R. and Prior, R. L. (2007). Development of a database for total antioxidant capacity in foods: A preliminary study. *Journal of Food Composition and Analysis*, 17, 407-422.