

Original Article

EXPLORING BANANA PEEL EXTRACT AS A POTENTIAL TREATMENT FOR PERIODONTITIS: AN ANIMAL MODEL STUDY

¹Dr. Maria Garcia and ²Dr. Chen Lin

¹University of Barcelona

²Shanghai Jiao Tong University, China

Abstract: Periodontitis, characterized by inflammation in the periodontal tissues, is primarily driven by the interplay between bacterial pathogens and the host tissue. Key bacterial culprits in periodontal diseases include *Porphyromonas gingivalis* and *Aggregatibacter actinomycetemcomitans*, which release lipopolysaccharides (LPS) as toxins. LPS-induced destruction of periodontal tissues triggers the release of inflammatory cytokines like IL-1, IL-6, and TNF- α . The consequential tissue damage is a leading cause of tooth loss in adults, potentially impacting oral health-related quality of life.

The initial treatment for periodontitis typically involves scaling and root planing, often complemented by adjuvant therapies like local hyaluronic acid gel application. These adjuvant therapies play a crucial role in promoting healing processes by exhibiting anti-inflammatory and antibacterial properties, while also stimulating cell growth.

Periodontal tissue regeneration primarily relies on the migration of nearby stem cells to the damaged site, where they differentiate into specialized cells, ultimately replacing the damaged tissue. Understanding these mechanisms and therapies is vital for enhancing periodontitis treatment outcomes

Keywords: Periodontitis, Inflammation, Bacterial pathogens, Adjuvant therapy, Tissue regeneration

Introduction

Periodontitis is inflammation located on periodontal tissue. Periodontitis occurs because of the interaction between the periodontal tissue and bacteria^{1, 2}. The most bacteria for periodontal diseases are *Porphyromonas gingivalis* and *Aggregatibacter actinomycetemcomitans*, which produce toxin called lipopolysaccharide. Periodontal tissue destruction induced by lipopolysaccharide and activated the inflammatory cytokine such as IL-1, IL-6 and TNF- α ³. Periodontal tissue destruction on periodontitis is the major cause of tooth loss on adult, this can be a problem because tooth loss may have bad implication on oral health-related quality of life⁴. The initial treatment performed for periodontitis are scaling and root planning, which followed by adjuvant or additional therapy such as local application of hyaluronic acid gel. Adjuvant therapy support and promote healing process which by its action as antinflammation, antibacterial and inducing cell growth.⁵ Periodontal tissue healing occurs when nearby stem cells migrate to the destructed tissue and differentiate into new specific cells and replace the destructed cells.

Original Article

Challenge in adjuvant the raphy availability

The obstacles in hyaluronic acid gel as adjuvant therapy for periodontitis is the unavailability in some country and high in price, thus make some scientist looking for new local natural resources which available with lower price.

Banana (*Musa paradisiaca* L.) peel waste

Banana (*Musa paradisiaca* L.) peel wastes usually either proceed into livestock feed or just thrown away. Banana peel waste is proposed as new local resource to substitute the hyaluronic acid gel as adjuvant therapy for periodontitis because banana peel extract contain active substances such as gallic acid, galocatechin, flavonoid and saponin, thus make banana peel have beneficial properties such as ant inflammation, antibacterial and inducing cells growth^{8,9}.

Material and Method

Materials

10% banana peel extract gel was obtained by maceration method then extracted using 96% ethanol. Sodium Carboxymethyl Cellulose (CMC-Na) was used as gelation agent, propyl paraben and aquadest added until reached the concentration of 10%. Hyaluronic acid gel was obtained from the Gengigel® which contain 0,2% hyaluronic acid. CMC-Na gel was obtained by mixing CMC-Na powder with aquadest until it reach the concentration 2%.

Experimental Design

Gingiva of maxillary molar was injected by 10^9 cfu/ml *A. actinomycetemcomitans* suspension in phosphat buffer saline once a day for five days to induce periodontitis. Fifty-seven of male *Rattus norvegicus* were divided in three groups. CMC-Na gel was given for the first group as negative control. Banana peel extract gel was applied for the second group, and 0,2% hyaluronic acid gel was applied for third group as positive control. Gel was applied topically on maxillary molar twice a day.

The rats were sacrificed on day 3, 5, 7, 14, 28. Samples in the form of periodontal tissue was carried out on 3rd, 5th, 7th, 14th, and 28th in each group. Angiogenesis and collagen density were observe histologically using binocular microscope and Optilab® in 400x magnification. Alveolar crest height was observed histologically and morphometrically.

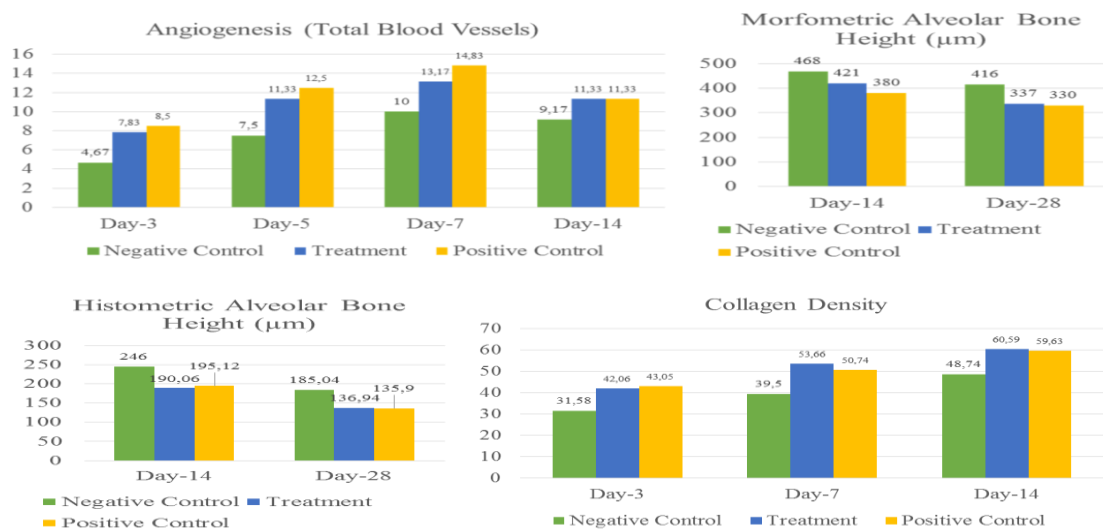
Data of angiogenesis, alveolar bone height and collagen density were taken from histopathologic counting and measuring under light microscope and Optilab®. To get angiogenesis data, we counted alveolar bone's blood vessel in haematoxylin eosin-dyed slide with Image Raster® software. Alveolar bone height were measured by drawing out a line from cemento enamel junction of first and second molar to apical with Image Raster® software. Besides, alveolar bone height were also measured morphometrically using Digimizer® software. The density of periodontal ligament's collagen was measured on Mallory trichrome dye with Image J programme.

The significance level established for all analyses was 5%. To see influence of those three gels to angiogenesis, alveolar bone height, and collagen density, we performed Two Way Anova analysis and continued by Post Hoc Test with Least Significant Difference (LSD) method.

Results

The results of the study showed application of 10% banana peel extract gel increased angiogenesis, alveolar bone height in histometric and morphmetric method and collagen density.

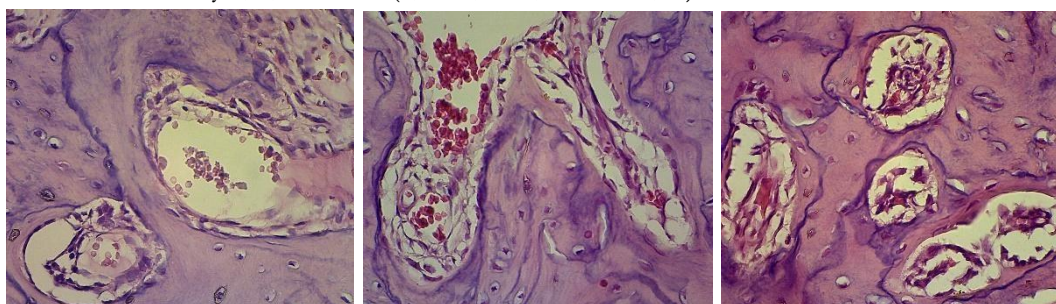
Original Article



Picture 1. Diagrams showed means of angiogenesis (A), morphometric alveolar bone height (B), histometric alveolar bone height (C) and collagen density (D).

Angiogenesis

Picture 1(A) showed amount of blood vessels in all groups increased from day 3 to 7 and decreased at day 14. The amount of blood vessels in rats given CMC-Na on day 3, 5, 7 and 14 were 4,67; 7,5; 10 and 9,17; while in rats given 10% banana peel extract were 7,83; 11,33; 13,17 and 11,33. Rats which given hyaluronat acid gel showed highest amount of blood vessels on day 3, 5, 7 and 14 (8,5; 12,5; 14,33 and 11,33).



(A) Negative Control

(B) Treatment

(C) Positive Control

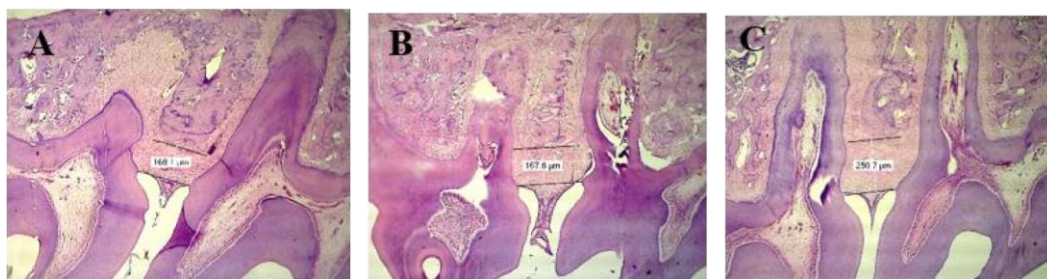
Two Ways Anova indicates significance difference ($p < 0,05$) of total blood vessels between three groups, which mean the three gels can influenced total blood vessels. Although in positive control groups showed highest amount of blood vessels in all day, based on LSD test, there is no significance different ($p > 0,05$) between treatment and positive control groups.

Alveolar Bone Height

According to morphometric and histometric method, in all groups from day 14 to 28 showed reduction of the distance between CEJ and alveolar bone crest (picture 1 (B and C)). It means the healing process was conducted and the alveolar bone crest got higher. The longest distance was owned by negative control group (morphometric: day 14 (468 μm) and day 28 (416 μm); histometric day 14 (246 μm) and day 28 (185,04 μm)) while the shortest by positive control group (morphometric: day 14 was 380 μm and 28 was 330 μm; histometric day 14 (195,12 μm) and day 28 (135,9 μm)). However, the distance between positive control and treatment (morphometric: day 14 (421 μm) and day 28 (337 μm); histometric day 14 (190,06 μm) and day 28 (136,94 μm) almost equal. The

Original Article

two way anova analysis showed significance difference ($p < 0,05$) between three groups and LSD test showing no significance different ($p > 0,05$) between treatment and positive control groups.




Picture 2. Positive control group (A), treatment group (B), negative control group (C)
Collagen Density

Based on picture 1(D), the density of periodontal ligament's collagen increased day by day. on day 7 and 14, application of 10% banana peel extract gel showed the most dense collagen (53,66% and 60,59%) rather than negative group (39,5% and 48,74%) and positive group (50,74% and 59,63%). Two Way Anova analysis indicates significance difference ($p < 0,05$) of collagen density between three groups and LSD test showing no significance different ($p > 0,05$) between treatment and positive control groups.

Discussion

Experimental results showed significant different between negative control group and positive control group either the treatment group. Topical application of hyaluronic acid gel (Gengigel®) and 10% banana peel extract gel could improve angiogenesis, collagen density, and alveolar bone height in periodontitis healing. These were caused by variable content among those gel. Bioactive components of yaluronic acid gel and banana peel extract gel have therapeutic effect that could promote periodontal tissue healing, while 2% CMC-Na gel does not have bioactive

components that could promote periodontal tissue healing.



Negative control group

Treatment group

Positive control group

The amount of blood vessel on control positive and treatment group showed unsignificant difference. According to that data, it could be told that banana peel extract gel could induce blood vessel proliferation as well as hyaluronic acid gel. Tannin in banana peel extract could promote VEGF expression that later could promote endotelproliferation¹⁰. Hyaluronic acid containslow weight molecular hyaluronic acid that could induce endotel proliferation as tanin in banana peel extract¹¹.

Flavonoid in banana peel extract could inhibit matrix metalloproteinase activity by bonding metal component of MMP^{12, 13}.Flavonoid was also could promote ILGF-1, PDGF, and TGF-β1 expression were later could promote fibroblast proliferation and collagen synthesis^{10, 14}. Gallocthecin in banana peel extract could increase tissue hidroxyproline¹⁵. Hidroxyproline was one of collagen matrix component¹⁶.Hyaluronic acid gel also could

Original Article

promote fibroblast proliferation and inhibit MMP ekspresion as well as banana peel extract gel, so that both of them could increase collagen density in periodontitis healing

Banana peel extract contain galat acid and gallocathecin that could inhibit oxidative stress reaction¹⁵. Inhibition of oxidative stress reaction could inhibit osteoclastogenesis by decreasing RANK expression and increasing osteoprotegrin production. Osteoprotegrin could bind RANK so that osteoprotegrin-RANK binding could prevent RANK and RANKL binding and prevent activation of osteoclast precursor become osteoclast¹⁸. Flavonoid of banana peel extract as antiinflammation could inhibit IL-1, IL-8, and TNF- α activity. Hyaluronic acid gel also has antioxidant and antiinflammation effect as well as banana peels extract¹¹. The difference between hyaluronic acid gel and banana peel extract gel are banana peel extract contain saponin that could induce bone morphogenetic protein expression. Increasing of BMP expression could inhibit osteoclast formation and induce osteoblast proliferation so that bone matrix production could increased¹⁹.

Summary

Banana (*Musa paradisiaca* L.) peel extract significantly improve periodontal healing by increasing alveolar bone height, collagen density on periodontal ligament and angiogenesis of alveolar bone, thus can be concluded that banana (*Musa paradisiaca* L.) peel extract gel can be used as adjuvant therapy candidate for periodontitis.

References

- Han, X., Lin, X., Yu, X., Lin, J., Kawai, T., LaRosa, K., & Taubman, M., Porphyromonas gingivalis Infection Associated Periodontal Bone Resorption is Dependent on Receptor Activator of NF- κ B Ligand, *Infect. Immun.* 2013; 81(5) : 1502–1509.
- Malik, R., Changela, R., Krishan, P., Gughani, S., & Bali, D., Virulence factors of Aggregatibacter actinomycetemcomitans : A status update, *J. Int. Clin. Dent. Res. Organ.* 2015; 7(2) : 137–145.
- Tomofuji, T., Irie, K., Sanbe, T., Azuma, T., & Morita, M., Periodontitis and Increase in Circulating Oxidative Stress, *Jpn. Denr. Sci. Res.* 2009; 45(1) : 46–51.
- Gerritsen, A. E., Allen, P. F., Witter, D. J., Bronkhorst, E. M., & Creugers, N. H. Tooth loss and oral health-related quality of life: a systematic review and meta-analysis. *Health and Quality of Life Outcomes.* 2010; 8 : 126.
- Smiley, C.J., Tracy, S.I., Abt, E., Michalowicz, B. S., & Estrich, C., Evidence-based clinical practice guideline on the nonsurgical treatment of chronic periodontitis by means of scaling and root planing with or without adjuncts, *The Journal of the American Dental Association.* 2015; 146(7) : 525–535
- Pejcic, A., Kojovic, D., Mirkovic, D., & Minie, I., Stem Cell for Periodontal Regeneration, *Balkan J. Med. Gen.* 2013; 1(16) : 7–12.
- Habiboallah, G., Mahdi, Z., Nasroallah, S., & Massoud, Z., Enhancement of Periodontal Healing by Application of a Novel Ointment Compared with Hyaluronic Acid , Histological Observation in Animal Model, *Mod. Res. Inflamm.* 2014; 3 : 71–81.
- Rajender, A., Andhare, M., & Musa, K., Banana Peel (*Musa paradisiaca*) : Can It be a Revolunationary Change in Periodontal Therapy? : A Review, *Int. J. Sci. Res.* 2016; 5(7) : 357–359.
- Sawen, D., & Sraun, T., The Waste Potency of Banana Skin (*Musa paradisiaca* L.) from Junkfood Salesman in Manokwari City, *Seminar Nasional Teknologi Peternakan dan Veteriner*, 2011; 558–563.

Original Article

- Sabirin, I. P. R., Maskoen, A. M., Hernowo, B. S., 2013, Peran Ekstrak Etanol Topikal Daun Mengkudu (*Morinda citrifolia* L .) pada Penyembuhan Luka Ditinjau dari Imunoekspresi CD34 dan Kolagen pada Tikus Galur Wistar, *MKB*, 45(4): 226–233.
- Litwiniuk, M., Krejner, N., Gizela, T., 2016, Hyaluronic Acid in Inflammation and Tissue Regeneration, *Wounds*, 28(3): 78-88.
- Stepcevic, T., Piljac, J., Berghe, D. Vanden., 2006, Effect of Different Flavonoids on Collagen Synthesis in Human Fibroblasts. *Plant Foods for Human Nutrition*, 61(1): 29–34.
- Nield-Gehrig, J. S., Willmann, D. E., 2011, *Foundations of Periodontics for the Dental Hygienist*, Lippincot William and Wilkins, Philadelphia.
- Budi, H. S., Kriswandini, I. L., Sudjarwo, S. A., 2016, Ambonese Banana Stem Sap (*Musa paradisiaca* var. *sapientum*) Effect on PDGF-BB Expressions and Fibroblast Proliferation in Socket Wound Healing, *International Journal of ChemTech Research*, 9(12): 558-564
- Pereira, A., Maraschin, M., 2015, Banana (*Musa* spp) from peel to pulp: Ethnopharmacology, source of bioactive compounds and its relevance for human health. *Journal of Ethnopharmacology*, 160: 149–163.
- Hamidpour, R., Hamidpour, Sohiela Hamidpour, M., Shahlari, M., Sohraby, M., & Shahlari, Nooshin Hamidpour, R., 2017, Russian olive (*Elaeagnus angustifolia* L.): From a variety of traditional medicinal applications to its novel roles as active antioxidant, anti-inflammatory, anti-mutagenic and analgesic agent, *Journal of Traditional and Contemporary Medicine*, 7(1): 24–29.
- Rajan, P., Bramappa, R., Rao, N. M., Pavalur, A. K., 2014, Hyaluronic Acid As an Adjunct to Scaling and Root Planning in Chronic Periodontitis, A Randomized Clinical Trial, *Journal of Clinical and Diagnostic Research*, 8(12): 11-14.
- Boyce, B. F., Xing, L., 2007, Biology of RANK, RANKL, and Osteoprotegrin, *Arthritis Res Ther*, vol(9)..
- Niu, Y. B., Kong, H., Li, Y. H., Fan, L., Pan, Y., Li, C., 2015, Radix Dipsaci Total Saponin Stimulate MC3T3-E1 Cell Differentiation Via the Bone Morphogenetic Protein-2/MAPK/Smad-dependent Runx2 Pathway, *Molecular Medicine Report*, 11(6),v pp.4468-4472.